

Ulcerative colitis complicated with Fournier's gangrene: A case report

Irina Bondoc¹, Marius Zamfir^{1,2}, Mara Mardare^{1,2}, Andrei Văcărașu¹, Alin Burlacu¹, Leila Ali³, Ariana Hudita⁴, Bianca Galateanu⁴, Octav Ginghină^{1,2}, Georgios Georgiadis^{5,6}, Charalampos Mamoulakis^{5,6}

AFFILIATION

- 1 Surgery 3 Department, Institute of Oncology 'Prof. Dr. A. Trestioreanu', Bucharest, Romania
- 2 Faculty of Medicine, University of Medicine and Pharmacy 'Carol Davila' from Bucharest, Bucharest, Romania
- 3 General Surgery Department, Emergency Clinical Hospital 'Sf. Ioan', Bucharest, Romania
- 4 Department of Biochemistry and Molecular Biology, University of Bucharest, Bucharest, Romania
- 5 Department of Urology, University General Hospital of Heraklion, Heraklion, Greece
- 6 School of Medicine, University of Crete, Heraklion, Greece

CORRESPONDENCE TO

Octav Ginghină, Surgery 3 Department, Institute of Oncology 'Prof. Dr. A. Trestioreanu', 252 Fundeni Avenue, 022328, district 2, Bucharest, Romania. E-Mail: octav.ginghina@umfcd.ro

KEYWORDS

ulcerative colitis, perianal fistula, clostridium difficile, Fournier's gangrene

Received: 28 December 2022, **Revised:** 8 January 2023, **Accepted:** 10 January 2023

Public Health Toxicol. 2023;3(1):3

<https://doi.org/10.18332/pht/159116>

ABSTRACT

Ulcerative colitis (UC) is a chronic immune-mediated inflammatory disorder affecting the colon, which displays an increasing incidence worldwide and is characterized by symptoms of rectal inflammation such as rectal bleeding, tenesmus and multiple stools daily. The diagnosis of UC is not easy to establish, therefore an overall interpretation of the clinical manifestations together with the results of the laboratory tests, lower gastrointestinal endoscopic examination (colonoscopy) and histopathology examination findings are advisable. The choice of therapy for ulcerative colitis is based on activity, severity and extension of lesions

and may include oral, systemic and topic therapy, as well as surgery. Patients with ulcerative colitis are generally immunocompromised predisposed to opportunistic infections. We present the case of a male aged 70 years diagnosed with ulcerative colitis with insidious evolution under systemic treatment, complicated with Fournier's gangrene which is a very rare complication of ulcerative colitis that should be kept in mind. A multidisciplinary approach including urologists and colorectal surgeons is the key to define best individualized management.

INTRODUCTION

Ulcerative colitis is a chronic immune-mediated complex inflammatory bowel disease (IBD) most likely resulting from an interplay between genetic susceptibility and epigenetic events that lead to dysregulation of the immune system associated with inflammation of the rectum, often extending proximally to other segments of the intestine. UC is characterized by symptoms of rectal inflammation: bleeding, tenesmus, and multiple stools daily.

At the cellular and molecular level, the colonocytes (colonic epithelial cells) are key players in the pathogenesis of ulcerative colitis as they display in this case an impaired expression of peroxisome proliferator-activated receptor γ

(PPAR- γ) which is a nuclear receptor that downregulates inflammation through nuclear factor kB (NF-kB)^{1,2}. Goblet cells may also play an important role in ulcerative colitis progression as they contribute to the integrity of the mucosal barrier by producing the trefoil factors^{3,4}. A permeable mucosal barrier was often associated with ulcerative colitis mainly due to the ease access of the bacteria through the normally impenetrable inner colon mucus layer⁵. More, patients with ulcerative colitis usually display dysbiosis characterized by an overall decreased biodiversity, decreased proportion of *Firmicutes* and increased proportion of *Gammaproteobacteria* and *Enterobacteriaceae*⁶. Interestingly, it is still not clear whether this dysbiosis is the cause or

the effect of the mucosal inflammation as UC associated inflammation may also be triggered by the increased activation and sensitivity of mature dendritic cells⁷. Also, an increased expression of Toll-like receptors (TLR) that mediate host response via stimulation of NF- κ B was also reported⁸. The inflammatory cascades triggered by NF- κ B produce signaling pro-inflammatory cytokines such as tumor necrosis factor α (TNF- α), IL-12 and IL-23^{9,10} which further potentiate lymphocyte activation and proliferation. The antigen presenting cells as well as the T cells activate the innate immune response which will subsequently activate the adaptive immune system^{9,10}. Some studies report UC as a modified T-helper-2 (Th2) disease as an imbalance between regulatory T cells and effector T cells was observed¹¹. The Th2 response activates natural killer T cells (NK) in the colon, which secrete IL-13 triggering epithelial cells apoptosis and tight junctions interruption¹¹ (Figure 1)

The diagnosis of UC is not easy to establish, therefore an overall interpretation of several approaches would be advisable. Consequently, the clinical manifestations should be interpreted together with the results of the laboratory tests, lower gastrointestinal endoscopic examination (colonoscopy) and histopathology examination findings. Also, an infectious etiology should be also ruled out.

Macroscopically, the endoscopic findings include loss of vascular markings, granularity and friability of the mucosa, erosions, ulcerations, spontaneous bleeding^{12,13}. Predictor factors of an aggressive course are: young age

(<40 years), extensive disease, large and deep ulcers, extra-intestinal symptoms, and an early need for corticoid therapy administration¹⁴.

The management of patients with UC includes remission of both clinical and endoscopic features. The choice of medical therapy is based on activity, severity, extent of inflammation and includes oral, topical and/or systemic therapy¹³. About 15% of UC patients develop an episode of severe colitis and approximately 30% of these patients need colectomy^{15,16}; furthermore, 10% of patients may need surgery in the first year of illness, mostly emergency procedures¹⁷. Studies have shown reduction in colectomy rates after infliximab therapy¹⁸.

Fournier's gangrene, described by Jean Alfred Fournier in 1883, is a necrotizing infection caused by multiple organisms, including aerobic/anaerobic species such as *Escherichia coli* (*E. coli*) and *Bacteroides fragilis* rapidly spreading through the superficial/deep fascial layers in the perineal, genital, or perianal regions, causing multiple organ failure/septic shock. The incidence rate has been reported to be approximately 1.6 per 100000 males and the mortality rate around 40% that can be reduced with early recognition/rapid application of adequate treatment protocols including administration of broad-spectrum antibiotics/emergency surgical debridement¹⁹. Diabetes mellitus, alcoholism, and immunosuppression are the most important risk factors²⁰. Fournier's gangrene is a very rare complication of UC reported in four patients to date²¹⁻²⁴.

Figure 1. Normal versus pathological state of the colonic inflammatory status (Created by BioRender.com)

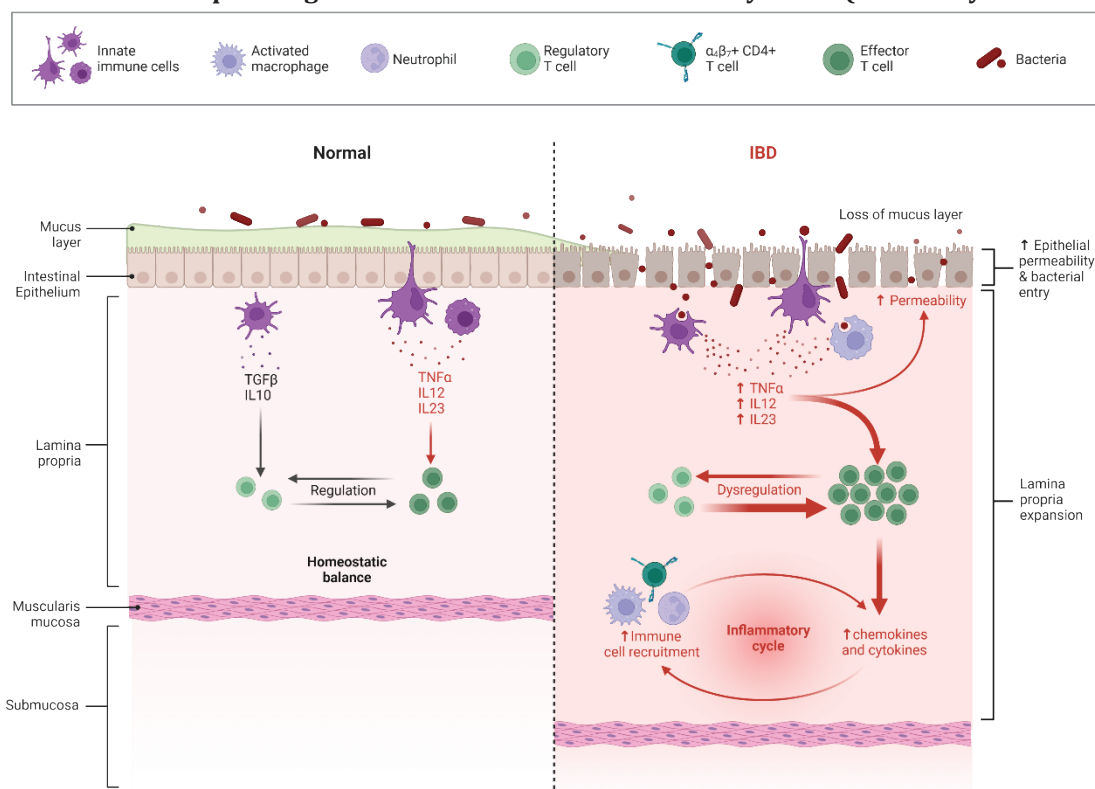


Figure 2. Colonoscopy highlighting left-sided colitis, Mayo score 3

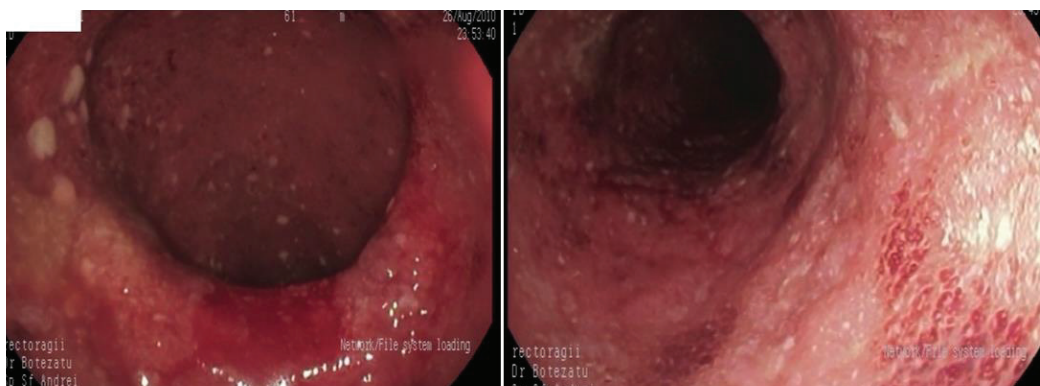


Figure 3. Colonoscopy highlighting severe left-sided colitis, Mayo score 3

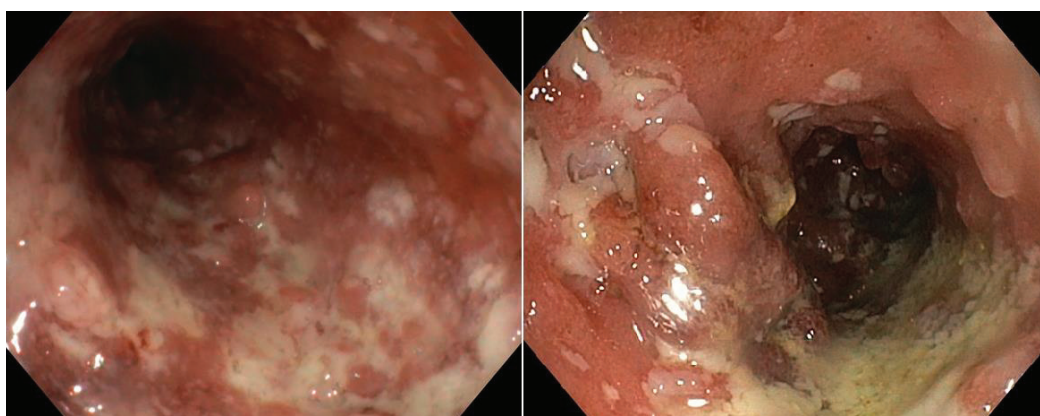
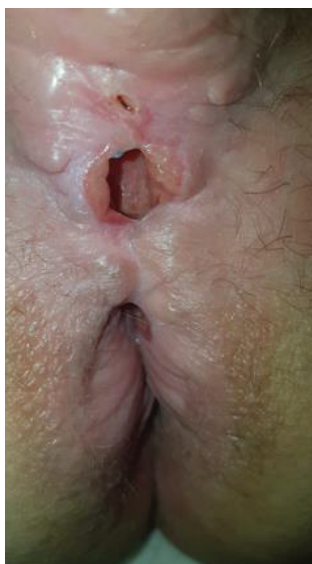

Figure 4. Complex recto-scrotal fistula



CASE PRESENTATION

We present the case of a man aged 70 years with UC. Patient's history revealed posttraumatic urethral stricture with multiple dilatations, multidrug-resistant urinary

tract infection (*Proteus mirabilis*, *Klebsiella*), *Clostridium difficile* (*C. difficile*) infection, and high blood pressure. He was evaluated in the gastroenterology department for diarrhea/bloody stools. Colonoscopy highlighted left-sided colitis, Mayo score 3 (Figure 2), for which oral therapy with Pentasa 3 g/day was initiated. Recurrent *C. difficile* infections followed. Surveillance colonoscopy after two years highlighted severe left-sided colitis, Mayo score 3 (Figure 3). Immunosuppressing therapy (Azathioprine 2 mg/kg) was added with clinical remission. Four months later he was referred to the Emergency Department with fever, scrotal pain and edema. The diagnosis of Fournier's gangrene was established. Immediate broad-spectrum intravenous antibiotics were used together with surgical debridement, left orchiectomy and permanent cystostomy. Postoperative outcome was favorable but a complex recto-scrotal fistula developed (Figure 4). Endoscopic evaluation showed persistent severe disease (Mayo score 3). Infliximab 5 mg/kg daily was added for 8 weeks with cessation of Pentasa. The patient displayed partial clinical response but soon showed secondary loss of response of Infliximab and therapy was switched to Adalimumab. Despite systemic therapy, the patient presented hyponatremia, hypokalemia, systemic inflammatory response (CRP 280 mg/L), severe anemia, which required multiple blood transfusions and 6–8 bloody

Figure 5. Contrast enhanced CT showing urethral and urinary bladder stone

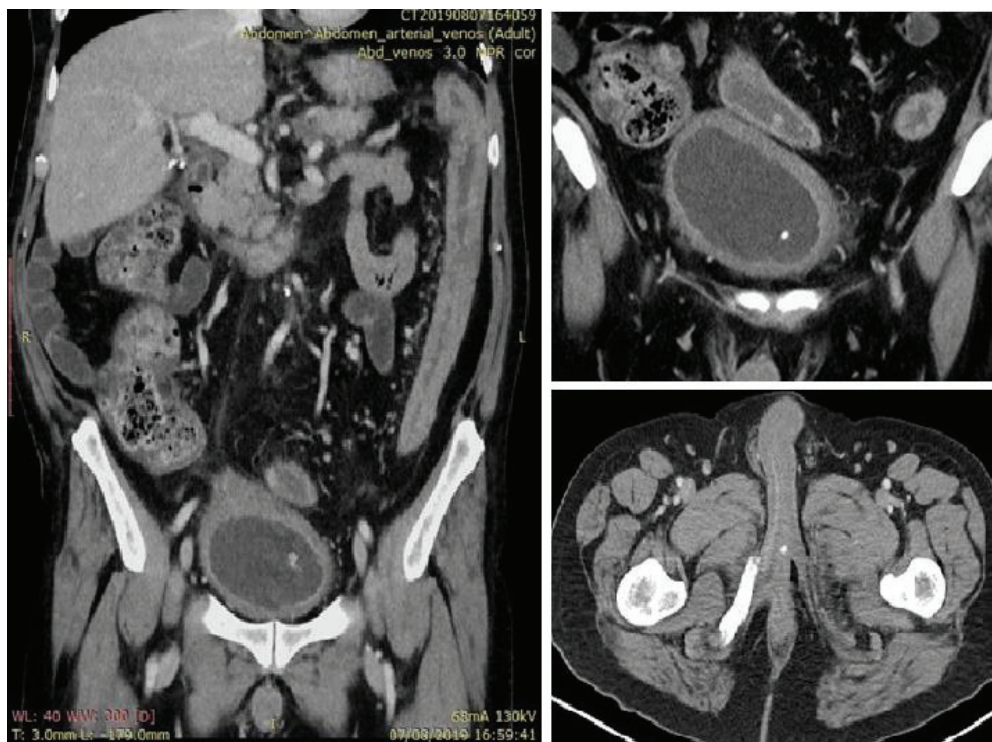
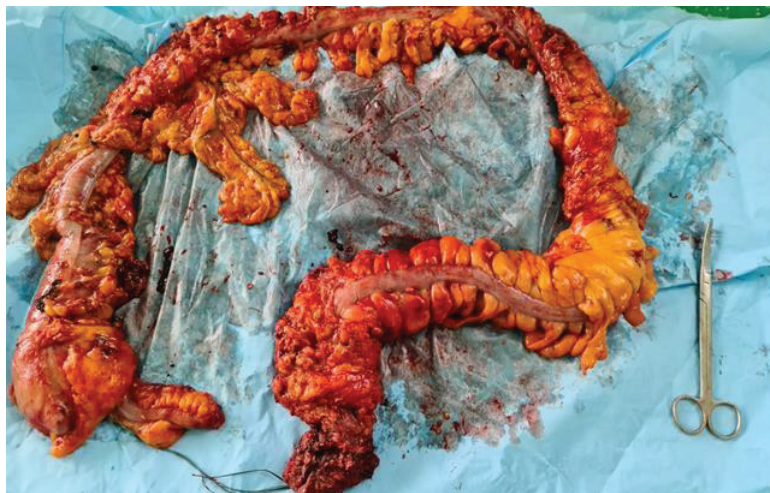

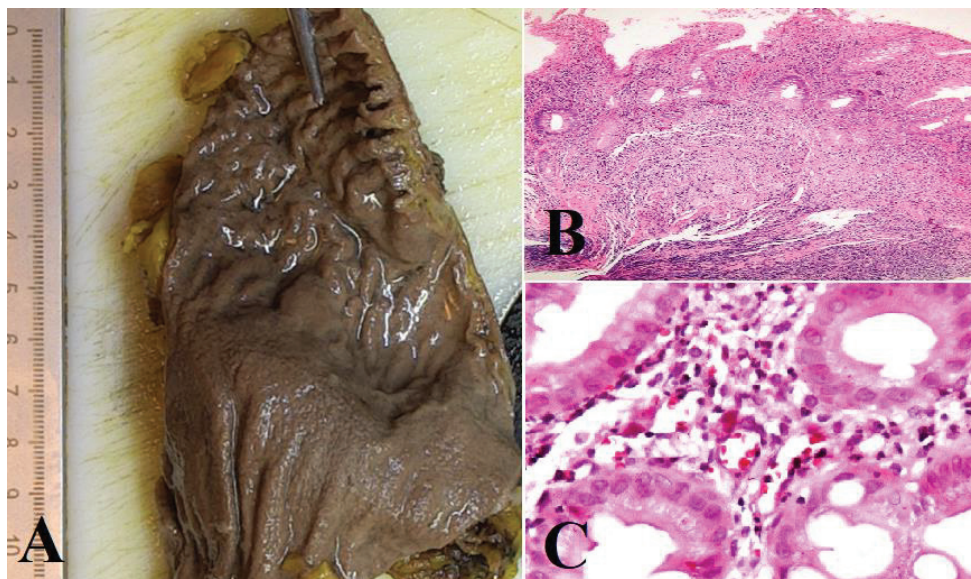
Figure 6. Proctocolectomy specimen



stools daily. Colonoscopy highlighted severe flare-up of UC (Mayo score 10). Corticoid therapy (Methylprednisolone 32 mg daily) was initiated, with partial clinical response. The patient was referred to the surgery department for proctocolectomy. At the time of admission, he presented anemia, urinary tract infection (MDR *Proteus mirabilis*), urinary bladder stones and *C. difficile* infection. Vancomycin was initiated and endoscopic stone extraction was practiced (Figure 5). The patient underwent surgery after *C. difficile* remission and laparoscopic proctocolectomy/end ileostomy-fistulectomy with perineorrhaphy, non-cutting seton had

been practiced (Figure 6). Postoperative outcome was initially favorable, but in day 6 he presented a worsening of clinical status, nausea, vomiting, profuse perspiration and leukocytosis. Stool samples highlighted *C. difficile* ileal infection, therefore Vancomycin therapy was resumed. In postoperative day 9, patient experienced ischemic stroke manifested with altered mental status, mixed aphasia and right hemiparesis, for which he was admitted to the intensive care unit. He was discharged after 19 days with lower right limb motor impairment, *C. difficile* negative, but persistence of *Proteus* urinary tract infection. Pathologic findings express

Figure 7. A) Macroscopic aspect showing granular appearance of the mucosa with loss of folds; B) Microscopic aspect showing large areas of ulceration and granulation tissue; and C) Microscopic aspect showing CMV inclusions



large areas of ulceration and granulation tissue with severe inflammation, pseudo-polypoid aspect of colonic mucosa, mild inflammation with intraepithelial neutrophils, with cytomegalovirus inclusions. No dysplasia was evidenced on the specimen (Figure 7).

DISCUSSION

The etiology and pathogenesis of UC is complex and resides from an imbalance between intestinal microbiota and mucosal immunity, resulting excessive local inflammation. Disrupted intestinal microbiota can cause perpetuation of inflammatory response and increasing of harmful bacteria in the intestine²⁵. *C. difficile*, a gram-positive anaerobic bacterium that causes pseudomembranous colitis, strongly recognized as a complication associated with UC patients, increasing the mortality, risk of hospitalization/surgery²⁶. Risk factors of developing *C. difficile* infection includes recent use of antibiotics, abdominal surgery, immunosuppressant therapy, gastric acid suppression and IBD²⁷. Previous studies showed that 18–25% of IBD patients experienced recurrence of *C. difficile* infection within 30 days following treatment^{28,29}; recurrence may be attributed either to endogenous persistence or to contamination by a new strain³⁰. Changes in the terminal ileal epithelium after ileostomy create a colon-like environment, which might explain the frequent development of *C. difficile* ileitis after a total colectomy with end ileostomy³¹.

Other enteric infections associated with UC have also been reported as a consequence of disrupted intestinal microbiota, most prevalent being infection with *E. coli*². Fournier's gangrene is a polymicrobial necrotizing fasciitis

or myonecrosis of the perineal, perianal and genital regions, with a rapid progression and high mortality rate ranging from 15% to 50%³². The most common etiologic bacteria in UC are *E. coli* followed by *Bacteroides* and streptococcal species²⁰, while other conditions such as diabetes, alcoholism, and immunosuppression rank as the most important risk factors³³. Fournier's gangrene associated with IBD has been reported to date only in four cases^{21–24}. Prompt diagnosis hemodynamic stabilization, administration of broad-spectrum antibiotics, analgesia and wide debridement, combined with colostomy/cystostomy if needed, are the mainstay for successful therapy²⁴. Perianal fistulous disease (PFD) in patients known with IBD, is more frequently associated with Crohn's disease, than UC (34% vs 4%, respectively)^{34,35}. Perianal abscess or fistula is a disabling complication that requires surgical intervention. Patients with simple perianal fistula require fistulotomy or fistulectomy; those with complex fistula with risk of sphincter injury may imply usage of non-cutting setons^{36,37}.

Surgery setting in UC (urgent, emergent or elective) depends on disease stage and patient's status. Patients with extended disease/no-response to medical therapy are candidates to proctocolectomy with ileoanal pouch or end ileostomy. Laparoscopic surgery in experienced hands is a safe, feasible solution for elective surgical treatment conferring advantages of minimally invasive approach such as low intraoperative blood loss and early recovery of the patient associated with shorter hospital stay³⁸. Restoration of continuity is often possible, however, with no guarantee of a good pouch function. More, leaking anastomosis and/or subsequent pelvic sepsis are difficult to approach in the

absence of other standard methods than transanal irrigation, percutaneous or surgical drainage. Chronic pelvic sepsis is associated with poor pouch function and pouch failure with development of persisting presacral sinus³⁹⁻⁴¹. Pelvic sepsis should be aggressively treated in order to avoid the long-term complications.

CONCLUSION

Patients with UC are generally immunocompromised. Fournier's gangrene is a very rare complication that should be kept in mind. A multidisciplinary approach including urologists and colorectal surgeons is the key to define best individualized management.

REFERENCES

- Dubuquoy L, Jansson EA, Deeb S, et al. Impaired expression of peroxisome proliferator-activated receptor gamma in ulcerative colitis. *Gastroenterology*. 2003;124(5):1265-1276. doi:10.1016/s0016-5085(03)00271-3
- Jiang C, Ting AT, Seed B. PPAR-gamma agonists inhibit production of monocyte inflammatory cytokines. *Nature*. 1998;391(6662):82-86. doi:10.1038/34184
- Mashimo H, Wu DC, Podolsky DK, Fishman MC. Impaired defense of intestinal mucosa in mice lacking intestinal trefoil factor. *Science*. 1996;274(5285):262-265. doi:10.1126/science.274.5285.262
- Podolsky DK, Isselbacher KJ. Glycoprotein composition of colonic mucosa. Specific alterations in ulcerative colitis. *Gastroenterology*. 1984;87(5):991-998.
- Johansson ME, Gustafsson JK, Holmén-Larsson J, et al. Bacteria penetrate the normally impenetrable inner colon mucus layer in both murine colitis models and patients with ulcerative colitis. *Gut*. 2014;63(2):281-291. doi:10.1136/gutjnl-2012-303207
- Frank DN, St Amand AL, Feldman RA, Boedeker EC, Harpaz N, Pace NR. Molecular-phylogenetic characterization of microbial community imbalances in human inflammatory bowel diseases. *Proc Natl Acad Sci USA*. 2007;104(34):13780-13785. doi:10.1073/pnas.0706625104
- Hart AL, Al-Hassi HO, Rigby RJ, et al. Characteristics of intestinal dendritic cells in inflammatory bowel diseases. *Gastroenterology*. 2005;129(1):50-65. doi:10.1053/j.gastro.2005.05.013
- Zhang FX, Kirschning CJ, Mancinelli R, et al. Bacterial lipopolysaccharide activates nuclear factor-kappaB through interleukin-1 signaling mediators in cultured human dermal endothelial cells and mononuclear phagocytes. *J Biol Chem*. 1999;274(12):7611-7614. doi:10.1074/jbc.274.12.7611
- Sands BE, Kaplan GG. The role of TNFalpha in ulcerative colitis. *J Clin Pharmacol*. 2007;47(8):930-941. doi:10.1177/0091270007301623
- Ordás I, Eckmann L, Talamini M, Baumgart DC, Sandborn WJ. Ulcerative colitis. *Lancet*. 2012;380(9853):1606-1619. doi:10.1016/S0140-6736(12)60150-0
- Heller F, Florian P, Bojarski C, et al. Interleukin-13 is the key effector Th2 cytokine in ulcerative colitis that affects epithelial tight junctions, apoptosis, and cell restitution. *Gastroenterology*. 2005;129(2):550-564. doi:10.1016/j.gastro.2005.05.002
- Fumery M, Singh S, Dulai PS, Gower-Rousseau C, Peyrin-Biroulet L, Sandborn WJ. Natural History of Adult Ulcerative Colitis in Population-based Cohorts: A Systematic Review. *Clin Gastroenterol Hepatol*. 2018;16(3):343-356. doi:10.1016/j.cgh.2017.06.016
- Rubin DT, Ananthakrishnan AN, Siegel CA, Sauer BG, Long MD. ACG Clinical Guideline: Ulcerative Colitis in Adults. *Am J Gastroenterol*. 2019;114(3):384-413. doi: 10.14309/ajg.0000000000000152
- Dassopoulos T, Cohen RD, Scherl EJ, Schwartz RM, Kosinski L, Regueiro MD. Ulcerative Colitis Care Pathway. *Gastroenterology*. 2015;149(1):238-45. doi: 10.1053/j.gastro.2015.05.036
- Carter MJ, Lobo AJ, Travis SP; IBD Section, British Society of Gastroenterology. Guidelines for the management of inflammatory bowel disease in adults. *Gut*. 2004;53(Suppl 5):V1-V16. doi:10.1136/gut.2004.043372
- Leijonmarck CE, Persson PG, Hellers G. Factors affecting colectomy rate in ulcerative colitis: an epidemiologic study. *Gut*. 1990;31(3):329-33. doi: 10.1136/gut.31.3.329
- Langholz E, Munkholm P, Davidsen M, Binder V. Colorectal cancer risk and mortality in patients with ulcerative colitis. *Gastroenterology*. 1992;103(5):1444-1451. doi: 10.1016/0016-5085(92)91163-x
- Järnerot G, Hertervig E, Friis-Liby I, et al. Inliximab as rescue therapy in severe to moderately severe ulcerative colitis: a randomized, placebo-controlled study. *Gastroenterology*. 2005;128(7):1805-1811. doi: 10.1053/j.gastro.2005.03.003
- Lewis GD, Majeed M, Olang CA, et al. Fournier's Gangrene Diagnosis and Treatment: A Systematic Review. *Cureus*. 2021;13(10):e18948. doi:10.7759/cureus.18948
- Marinella MA. Group C streptococcal sepsis complicating Fournier gangrene. *South Med J*. 2005;98(9):921-923. doi: 10.1097/01.smj.0000177354.44532.9f
- Brings HA, Matthews R, Brinkman J, Rotolo J. Crohn's disease presenting with Fournier's gangrene and enterovesical fistula. *Am Surg*. 1997;63(5):401-405.
- Cohen M, Tamir E, Abu-Abid S, et al. The diagnosis and treatment of Fournier's gangrene. *Harefuah*. 1998;135(9):360-407.
- Jiang T, Covington JA, Haile CA, Murphy JB, Rotolo FS, Lake AM. Fournier gangrene associated with Crohn disease. *Mayo Clin Proc*. 2000;75(6):647-649. doi: 10.4065/75.6.647
- Katsanos KH, Ignatiadou E, Sarandi M, et al. Fournier's gangrene complicating ulcerative pancolitis. *J Crohns Colitis*. 2010;4(2):203-206. doi: 10.1016/j.crohns.2009.11.006
- Shen ZH, Zhu CX, Quan YS, et al. Relationship between intestinal microbiota and ulcerative colitis: Mechanisms and clinical application of probiotics and fecal microbiota transplantation. *World J Gastroenterol*. 2018;24(1):5-14. doi: 10.3748/wjg.v24.i1.5

26. Ananthkrishnan AN, McGinley EL, Binion DG. Excess hospitalisation burden associated with *Clostridium difficile* in patients with inflammatory bowel disease. *Gut*. 2008;57(2):205-210. doi: 10.1136/gut.2007.128231
27. Dineen SP, Bailey SH, Pham TH, Huerta S. *Clostridium difficile* enteritis: A report of two cases and systematic literature review. *World J Gastrointest Surg*. 2013;5(3):37-42. doi: 10.4240/wjgs.v5.i3.37
28. Kariv R, Navaneethan U, Venkatesh PG, Lopez R, Shen B. Impact of *Clostridium difficile* infection in patients with ulcerative colitis. *J Crohns Colitis*. 2011;5(1):34-40. doi: 10.1016/j.crohns.2010.09.007
29. Issa M, Ananthkrishnan AN, Binion DG. *Clostridium difficile* and inflammatory bowel disease. *Inflamm Bowel Dis*. 2008;14(10):1432-1442. doi: 10.1002/ibd.20500
30. Barbut F, Richard A, Hamadi K, Chomette V, Burghoffer B, Petit JC. Epidemiology of recurrences or reinfections of *Clostridium difficile*-associated diarrhea. *J Clin Microbiol*. 2000;38(6):2386-2388. doi: 10.1128/JCM.38.6.2386-2388.2000
31. Apel R, Cohen Z, Andrews CW Jr, McLeod R, Steinhart H, Odze RD. Prospective evaluation of early morphological changes in pelvic ileal pouches. *Gastroenterology*. 1994;107(2):435-443. doi: 10.1016/0016-5085(94)90169-4
32. Levenson RB, Singh AK, Novelline RA. Fournier gangrene: role of imaging. *Radiographics*. 2008;28(2):519-528. doi:10.1148/rg.282075048
33. Graf H, Luger A, Pflüger H, Syre G, Gebhart W. Fournier-Gangrän: Eine seltene Komplikation bei multiplem Myelom. Fournier gangrene: a rare complication of multiple myeloma. *Hautarzt*. 1983;34(6):289-291.
34. Lee MJ, Heywood N, Sagar PM, Brown SR, Fearnhead NS; ACPGIBI Perianal Crohn's Disease Group. Association of Coloproctology of Great Britain and Ireland consensus exercise on surgical management of fistulating perianal Crohn's disease. *Colorectal Dis*. 2017;19(5):418-429. doi: 10.1111/codi.13672
35. Zabana Y, Van Domselaar M, Garcia-Planella E, et al. Perianal disease in patients with ulcerative colitis: A case-control study. *J Crohns Colitis*. 2011;5(4):338-341. doi:10.1016/j.crohns.2011.02.011
36. de Las Casas SG, Alvarez-Gallego M, Martínez JAG, et al. Management of perianal fistula in inflammatory bowel disease: identification of prognostic factors associated with surgery. *Langenbecks Arch Surg*. 2021;406(4):1181-1188. doi:10.1007/s00423-021-02100-4
37. Choi YS, Kim DS, Lee DH, et al. Clinical Characteristics and Incidence of Perianal Diseases in Patients With Ulcerative Colitis. *Ann Coloproctol*. 2018;34(3):138-143. doi:10.3393/ac.2017.06.08
38. Øresland T, Bemelman WA, Sampietro GM, et al. European evidence based consensus on surgery for ulcerative colitis. *J Crohns Colitis*. 2015;9(1):4-25. doi:10.1016/j.crohns.2014.08.012
39. Chow A, Tilney HS, Paraskeva P, Jeyarajah S, Zacharakis E, Purkayastha S. The morbidity surrounding reversal of defunctioning ileostomies: a systematic review of 48 studies including 6,107 cases. *Int J Colorectal Dis*. 2009;24(6):711-723. doi:10.1007/s00384-009-0660-z
40. Sagar PM, Pemberton JH. Intraoperative, postoperative and reoperative problems with ileoanal pouches. *Br J Surg*. 2012;99(4):454-468. doi: 10.1002/bjs.8697
41. Poggioli G, Marchetti F, Sella S, Laureti S, Stocchi L, Gozzetti G. Redo pouches: salvaging of failed ileal pouch-anal anastomoses. *Dis Colon Rectum*. 1993;36(5):492-496. doi: 10.1007/BF02050016

CONFLICTS OF INTEREST

The authors have each completed and submitted an ICMJE form for disclosure of potential conflicts of interest. The authors declare that they have no competing interests, financial or otherwise, related to the current work. This research was partially funded by the European Union's Horizon Europe framework program project name: European Partnership for the Assessment of Risks from Chemicals (PARC).

FUNDING

This research was partially funded by the European Union's Horizon Europe framework program project name: European Partnership for the Assessment of Risks from Chemicals (PARC).

ETHICAL APPROVAL AND INFORMED CONSENT

Ethical approval and informed consent were not required for this study.

DATA AVAILABILITY

The data supporting this research are available from the authors on reasonable request.

AUTHORS' CONTRIBUTIONS

MM, AV and OG conceived the work idea and formed the layout of the manuscript. AH, BG, GG and CM wrote the final draft of the manuscript. IB, MZ, AB and LA contributed in the patient data collection and carried out literature search. MM, BG, CM and OG contributed to the final manuscript format adjustments and content editing. All authors read and approved the final manuscript.

PROVENANCE AND PEER REVIEW

Not commissioned; externally peer reviewed.