

# Toxicity evaluation of *Ziziphus spina-christi* fruit on Wistar rats

Khadija Aliyu Nuru<sup>1</sup>, Usman Adamu Garkuwa<sup>2</sup>, Hindatu Yusuf<sup>3</sup>, Habibu Tijjani<sup>4</sup>, Aminu Umar Kura<sup>5</sup>

## AFFILIATION

- 1 Department of Biochemistry, Faculty of Science, Bauchi State University Gadau, Bauchi State, Nigeria
- 2 Department of Physiology, Faculty of Basic Medical Sciences, Bauchi State University Gadau, Bauchi State, Nigeria
- 3 Department of Microbiology and Biotechnology, Faculty of Science, Federal University Dutse, Jigawa State, Nigeria
- 4 Department of Environmental Health Science, National Open University of Nigeria, Abuja, Nigeria
- 5 Department of Pharmacology, Faculty of Basic Medical Sciences, Bauchi State University Gadau, Bauchi State, Nigeria

## CORRESPONDENCE TO

Aminu Umar Kura. Department of Pharmacology, Faculty of Basic Medical Sciences, Bauchi State University Gadau, PMB 65, Bauchi State, Nigeria.  
E-mail: [aukura@basug.edu.ng](mailto:aukura@basug.edu.ng)

## KEYWORDS

toxicity, *Ziziphus spina-christi*, histology, liver toxicity, renal toxicity

**Received:** 8 February 2023, **Revised:** 19 February 2024, **Accepted:** 24 February 2024

Public Health Toxicol. 2024;4(1):4

<https://doi.org/10.18332/pht/189288>

## ABSTRACT

**INTRODUCTION** *Ziziphus spina-christi* produces sweet and highly nutritious fruits that are usually eaten fresh. The plant has various medicinal and nutritional values. The study aimed at evaluating the acute toxicity of *Z. spina-christi* fruit on Wistar rats.

**METHODS** An experimental animal study was carried out to evaluate the acute toxicity potential of *Z. spina-christi* fruit extract. The fruits were extracted by the maceration method and a qualitative phytochemical analysis was done to evaluate for secondary metabolites. A total of 15 young adult female Wistar rats were used for acute toxicity study based on the OECD 420 guidelines for testing of chemicals. Fixed-dose procedure using 2000 mg/kg of the extracts was employed. Groups were compared using one-way ANOVA for significant differences and Dunnett's post hoc test was used where differences existed. Data are represented as mean  $\pm$  SEM, and a  $p < 0.05$  was considered statistically significant.

**RESULTS** Phytochemical analysis revealed the presence of alkaloids, flavonoids, terpenoids, tannins, saponins, saponins glycosides, steroids, phytosteroids, carbohydrate and some volatile oil. No sign of toxicity was recorded after 2000 mg/kg dose of the extract was given to the rats. The liver architecture was well preserved in the normal control

group; however, the liver architecture of the two treated groups was distorted. Tissue necrosis was seen as evidence by perinuclear vacuolation, and also present were a few inflammatory cells. Kidneys of experimental rats treated with 2000 mg/kg aqueous extract of *Z. spina-christi* fruit for 14 days showed glomerular atrophy and generalized tissue degeneration as seen by the dissolution of both nuclear and cytoplasmic components.

**CONCLUSIONS** The results shows that *Z. spina-christi* fruit aqueous and ethanol extracts causes liver and kidney derangement seen in the altered urea, creatinine, ALT and AST levels. Some atrophic changes, inflammation and architectural distortion of both liver and kidney, and histology confirmed the toxic potential of this fruit within the tested dose in the rats. These findings suggest that caution should be exercised when consuming *Z. spina-christi* fruit, particularly at high doses or for extended periods.

**ABBREVIATIONS** OECD: Organization for Economic Co-operation and Development, ALT: alanine transferase, AST: aspartate transferase, SOD: superoxide dismutase, CAT: catalase, GSHPX: glutathione peroxidase, MDA: malondialdehyde, DPPH: 1,1-diphenyl-2-picrylhydaryl, SoP: standard operations procedure, CREA: creatine, AEZSC: aqueous extract of *Ziziphus spina-christi*, LD50: lethal dose, EC50: half maximal effective concentration

## INTRODUCTION

The basic needs of food, shelter, clothing, fuel, ornamentals and flavoring can be provided by plants and they are considered as source of medication for thousands of years<sup>1</sup>.

Over a quarter of world prescribed drugs are derived from plant extracts<sup>2</sup>. A plant used for the extraction of substances, either for direct medical use or for the synthesis of medicinal compounds which can be used for therapeutic

purpose or as a precursor for the synthesis of useful drugs is termed a medicinal plant<sup>3</sup>. Numerous explorative studies carried out over several decades on certain herbs found them to have definite action on nervous, circulatory, respiratory, digestive and urinary systems; as well as the sexual organs, the skin, vision, hearing and taste<sup>4</sup>. Other than the beneficial therapeutic effects, these plants may have deleterious side effects as well, ranging from simple electrolyte derangements, architectural distortion of major organs like the liver and kidney, to carcinogenesis in the extreme cases and its consequent cancer development in the future<sup>5</sup>.

*Ziziphus spina-christi* commonly known as Christ's Thorn Jujube is a good example of plants with medicinal effects<sup>1,6-8</sup>. Important nutrients and phytochemicals in all parts of *Z. spina-christi* were reported from analysis done by researchers in the past<sup>8,9</sup>. Betulinic and ceanothic acids, various flavonoids, saponins, erols, tannins, triterpenes, glycoside and flavonoids, lipids, protein, free sugar and mucilage were all extracted from the leaves of the plant<sup>9-12</sup>.

Among the popular use of *Z. spina-christi* in traditional medicine is in the treatment of pain and inflammatory related ailments such as arthritis, obesity, diabetes, skin infections, and loss of appetite, fever, pharyngitis, bronchitis, anemia, diarrhea, and insomnia<sup>13</sup>. The promotion of fresh-wound healing, treatment of dysentery, dandruff, asthma and for the cure of eye diseases are other areas of this plant usage traditionally<sup>6,14</sup>.

The plant *Z. spina-christi* has several antioxidants that help in protecting the human body against oxidative damage from reactive free radicals seen in cancers, ischemic heart disease, Alzheimer's, Parkinson's disease, atherosclerosis, and aging<sup>13</sup>. Natural products as a whole and/or their constituents possess efficient ant-oxidative characteristics linking them to anti-cancer, anti-inflammatory, anti-aging and hypolipidemic activities<sup>13,15</sup>. Fruits from *Z. spina-christi* inhibit lipid peroxidation in CCl<sub>4</sub> exposed animals<sup>13</sup>. Remarkably, the methanolic extract of the fruits at a dose of 200 mg/kg increases the activities of catalase (CAT), superoxide dismutase (SOD), glutathione peroxidase (GSHPx) and GSH in hepatic tissue, all of which are endogenous antioxidant enzymes that protect our system against oxidative stress and its consequent negative effects<sup>16</sup>. This study aimed to evaluate the acute toxicity potential of *Z. spina-christi* fruit extracts on Wistar rats.

## METHODS

An experimental animal study was carried out to evaluate the acute toxicity potential of *Z. spina-christi* fruit extracts. *Z. spina-christi* fruit was purchased dry from Muda Lawan market Bauchi local government area of Bauchi State from the local vendors. The plant was taken to the herbarium in the Department of Biological Science Bauchi State University Gadau, and was authenticated by a taxonomist from the Department of Biological Sciences, Bauchi State University

Gadau. The *Z. spina-christi* fruits were washed to remove dust and then drained. It was then grinded into powder using mortar and pestle and then subjected to extraction using the maceration method.

In brief about 100 g of *Z. spina-christi* fruit powder were weighed with an analytical weighing balance and transferred to a 1000 mL beaker to which 1000 mL of 80% ethanol were added. Another 100 g of the sample were dissolved in 1000 mL of distilled water. The two beakers containing the mixtures were allowed to stand for 72 h and then filtered using filter paper, and the filtrate was concentrated at 50°C on a water bath. The percentage yield was calculated as follows:

$$\text{Percentage yield} = (\text{Weight of extract}/\text{Original weight}) \times 100\%$$

The phytochemical analysis was done for qualitative determination. The analyses included: alkaloids, flavonoids, tannins, terpenoids, saponins, chalcones, phlobatannins, anthraquinones, steroids, phytosteroids, reducing sugars and cardiac glycosides, according the method outlined by the Association of Analytical Chemist<sup>17,18</sup>.

A total of 15 animals were used for acute toxicity study using OECD 420 guidelines for testing of chemicals, using a fixed-dose procedure with 2000 mg/kg of the extract<sup>19</sup>. The animals were obtained from animal house of the Department of Pharmacology, Faculty of Basic Medical Science, Bauchi State University Gadau. They were fed with a standard pellet diet and kept under standard environmental conditions of laboratory temperature and water *ad libitum*. All the animals were housed in polypropylene cages. The animals were kept under alternate cycle of darkness and light of 12 h. They were acclimatized to the laboratory conditions for 2 weeks before starting the experiment. The animals were fasted overnight before the onset of each activity. The animal experimental protocols were approved by Faculty of Basic Medical Sciences' Research and Ethics Committee (FBMSREC No. BASUG/FBMS/REC/VOL. 2/002) Bauchi State University Gadau. The rats were young adult female albino Wistar rats, nulliparous and non-pregnant. The animals were grouped into 3 cages containing 5 animals each. They were administered with a single oral dose of aqueous and ethanol extracts of *Z. spina-christi* of 2000 mg/kg and observed for 14 days. The control group received distilled water at 1 mL/kg body weight. The weight of the animals was recorded at days 0, 7 and 14.

At the end of the experiment, the animals were humanely sacrificed. Blood, liver and kidney samples were collected for analysis. The blood was allowed to clot and serum separated and the following investigations were carried out in the serum sample: liver enzymes (AST and ALT) determination of electrolytes (Na, K, Cl<sup>-</sup>, HCO<sub>3</sub><sup>-</sup>) urea and creatinine and liver proteins (Bil, Con. Bil, Uncon. Bil, total protein, albumin and globulin).

### Determination of liver enzymes (AST and ALT)

The liver function test was carried out for aspartate aminotransferase (AST) and alanine aminotransferase (ALT) colorimetrically at 546 nm using a method described by Reitman and Frankel<sup>20</sup>.

#### Alanine aminotransferase (ALT)

Alanine aminotransferase was determined using the UV/IFCC method (kit obtained from Randox Laboratories, Ardmore, Co. Antrim, UK). A 500  $\mu$ L of R1 reagent was pipetted to test tubes labelled blank and test. To which 100  $\mu$ L of distilled water were added to the test tube labelled blank and 100  $\mu$ L of sample to the test tube labelled test. Mixed and allowed to stand for exactly 30 min at 37°C. About 500  $\mu$ L of R2 reagent were added to the test tubes labelled blank and test, mixed and allowed to stand for exactly 20 min at 20–25°C. Then 5000  $\mu$ L of 0.4N sodium hydroxide were added and mixed. Absorbance was read against reagent blank at 546 nm wavelength after 5 min (calculation: conc. of ALT=test  $0.25 \times 4$ ).

#### Aspartate aminotransferase (AST)

Aspartate aminotransferase was determined using the UV/IFCC method using the same kit as before. A 500  $\mu$ L of R1 reagent were pipetted into test tubes labelled as blank and test. In the test tube blank, 100  $\mu$ L of distilled water were added and 100  $\mu$ L of sample to the test tube labelled as test, mixed and allowed to stand for exactly 30 min at 37°C. R2 reagent (500  $\mu$ L) was added to the test tubes, mixed and allowed to stand for exactly 20 min at 20–25°C. About 5000  $\mu$ L of 0.4N sodium hydroxide were added and mixed. Absorbance was read against reagent blank at 546 nm wavelength after 5 min (calculation: conc. of AST=test  $0.022 \times 7$ ).

### Determination of plasma urea

The method of Chaney and Marbach<sup>21</sup> was used to determined urea concentration (kit obtained from Randox Laboratories, Ardmore, Co. Antrim, UK). Three test tubes were labelled as blank, standard and test, 10  $\mu$ L of sample were added into the test tube labelled test, 10  $\mu$ L of standard into the test tube labelled standard and 10  $\mu$ L of distilled water into the test tube labelled blank. Another 100  $\mu$ L of reagent I were added to all the three test tubes, mixed and incubated at 37°C for 10 min. And 2500  $\mu$ L of reagent II were added to all the three test tubes followed by another 2500  $\mu$ L of reagent III to all the test tubes, mixed and incubated at 37°C for 15 min. Absorbance was read at 546 nm against the blank (the color was stable for hours) (urea conc. = absorbance of sample/absorbance of standard  $\times$  conc. of standard).

### Determination of plasma creatinine

The method of Taussky<sup>22</sup> was used to determined creatinine concentration. The kit was obtained from Randox

Laboratories, Ardmore, Co. Antrim, UK. Test tubes were labelled as test, standard and blank, 100  $\mu$ L of standard were added to the test tube labelled standard, 100  $\mu$ L of distilled water to the test tube labelled blank and 100  $\mu$ L of sample were added to the test tube labelled test. Another 1000  $\mu$ L were added to all the three test tubes and then mixed. Absorbance was read after 30 s against distilled water (A1). After 2 min absorbance was read against blank at 492 nm [calculation: creatinine conc. = absorbance of sample (A2-A1)/absorbance of standard (A2-A1)  $\times$  conc. of standard].

### Determination of liver proteins.

Liver proteins such as bilirubin and conjugated bilirubin were determined using Randox reagents whereas total protein using biuret reagent and albumin with bromocresol reagents

### Determination of total bilirubin

A volume of 200  $\mu$ L of reagent 1 was pipetted into test tubes labelled blank and test, 50  $\mu$ L of reagent 2 were also added into the test tube labelled test, and 1000  $\mu$ L of reagent 3 into the test tube labelled blank. Then, 200  $\mu$ L of the sample were added into the test tubes labelled blank and test, mixed and allowed to stand for 10 min at 20–25°C. Finally, 1000  $\mu$ L of reagent 4 into the test tubes labelled blank and test, mixed and allowed to stand for 5–30 min at 20–25°C. Absorbance was read against the sample blank at 578 nm (calculation: total bilirubin conc. ( $\mu$ mol/L) = 185  $\times$  absorbance of sample).

### Determination of conjugated bilirubin

A volume 200  $\mu$ L of reagent 1 was added to the test tube labelled blank and test, 50  $\mu$ L of reagent 2 to the test tube labelled test, 200  $\mu$ L of 0.9% NaCl to both blank and test. Then, 200  $\mu$ L of sample were added to the test tubes labelled blank and test, mixed and allowed to stand for exactly 10 min at 20–25°C. Absorbance was read against the sample blank at 546 nm (calculation: direct bilirubin conc. ( $\mu$ mol/L) = 246  $\times$  absorbance of sample).

### Determination of unconjugated bilirubin concentration

Plasma indirect bilirubin concentration was estimated using the formula: Indirect bilirubin conc ( $\mu$ mol/L) = total bilirubin - direct bilirubin.

### Determination of total protein

Total plasma protein (TP) values were measured colorimetrically at 546 nm using the biuret method<sup>23</sup>. A 1000  $\mu$ L of biuret reagent were added into three test tubes labelled blank, standard and test. Then, 10  $\mu$ L of standard were added into the test tube labelled standard, 10  $\mu$ L of serum to the test tube labelled test, mixed well and incubated for 5 min at room temperature. Absorbance of standard and sample was read against reagent blank within 60 min at 546 nm. (calculation: conc. of standard = 6 g/dL. Total protein conc. (g/dL) = absorbance of test/absorbance of standard  $\times$  6).

### Determination of albumin

Test tubes were labelled as blank, standard and test, 1000 µL of reagent were added to all the three test tubes and 5 µL of standard to the test tube labelled standard, 5 µL of sample to the test tube labelled test, mixed and incubated for 10 min at room temperature (15–25°C). Absorbance of the sample and standard were read against the blank at 630 nm. The color was stable for 60 min at room temperature (calculation: conc. of standard = 5 g/dL. Conc. of albumin = absorbance of sample/absorbance of standard × conc. of standard).

### Determination of globulin

Plasma globulin concentration was determined using the formula: Globulin = Total serum protein - albumin.

### Histopathology of the liver and kidney

All the rats were sacrificed by exsanguinations after light ether inhalation anesthesia at the end of the experiment. The animals were subjected to post-mortem examination

**Table 1. Qualitative phytochemical contents of *Zizipus spina-christi* fruit aqueous and ethanol Extracts**

Phytochemicals	Aqueous extract	Ethanol extract
Alkaloids	+	++
Cardiac glycoside	-	+
Carbohydrate	++	++
Flavonoids	++	+++
Phytosteroids	+	+++
Saponins	+++	++
Saponins glycoside	+	++
Steroids	+	+++
Terpenoids	+	-
Tannins	+	+++
Volatile oil	-	+

AZSC: aqueous extract of *Z. spina-christi* fruit. EZSC: ethanol extract of *Z. spina-christi* fruit.

with collection of organs such as liver and kidneys. The tissues were fixed in 10% formalin for at least 48 h, in 4–5 µm paraffin sections and processed and stained with hematoxylin and eosin (H&E) for microscopic examination using established protocols<sup>24</sup>.

### Statistical analysis

Statistical analysis was carried out using mean ± standard error of mean (SEM) and analyzed with standard statistical software package for social science (SPSS) version 17.0 software using one-way analysis of variance (one-way ANOVA) and Dunnett's *post hoc* test for differences between multiple and two means, respectively. Differences were considered statistically significant at  $p < 0.05$ . Bar charts were drawn using Exel 2013 software.

## RESULTS

The percentage yield of aqueous extract was 35.59% and that of ethanol extract 46.68%. Alkaloids, steroids, saponins, flavonoids, terpenoids, saponins glycoside, phytosteroids, cardiac glycosides, tannins, volatile oil and carbohydrate in different proportion were the secondary metabolites obtained from the phytochemical analysis of the aqueous and ethanol extract of fruits of *Z. spina-christi*. Details of the phytochemicals obtained are shown in Table 1.

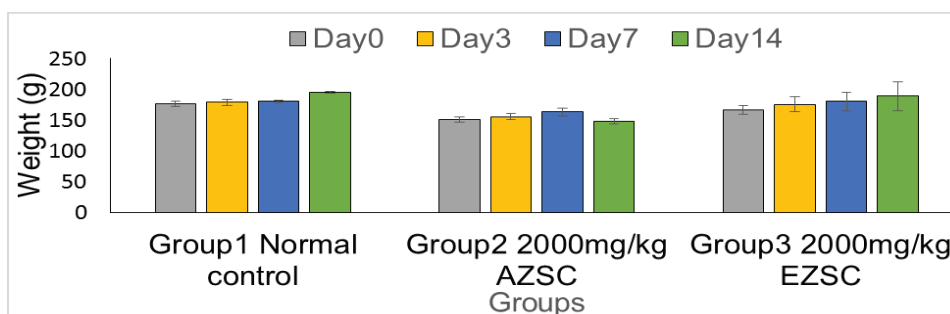
An acute toxicity using OECD guidelines was done with a

**Table 2. Effect of *Zizipus spina-christi* fruit aqueous and ethanol extracts on liver enzymes in experimental rats**

Groups	ALT	AST	AST/ALT
Normal control	4.13 ± 0.23*	22.49 ± 3.83	5:1
AZSC 2000 mg/kg	13.60 ± 0.40*	22.17 ± 1.43	2:1
EZSC 2000 mg/kg	12.11 ± 0.70*	21.43 ± 2.12	2:1

Activity of alanine aminotransferase and aspartate aminotransferase in experimental rats treated with 2000 mg/kg extracts. Values are expressed as the mean ± SEM of  $n=5$  and were analyzed using one-way ANOVA. \*Values are significantly different from the control group. AZSC: aqueous extract of *Z. spina-christi* fruit. EZSC: ethanol extract of *Z. spina-christi* fruit.

**Figure 1. Effect of *Ziziphus spina-christi* fruit aqueous and ethanol extracts on the body weight in experimental rats**



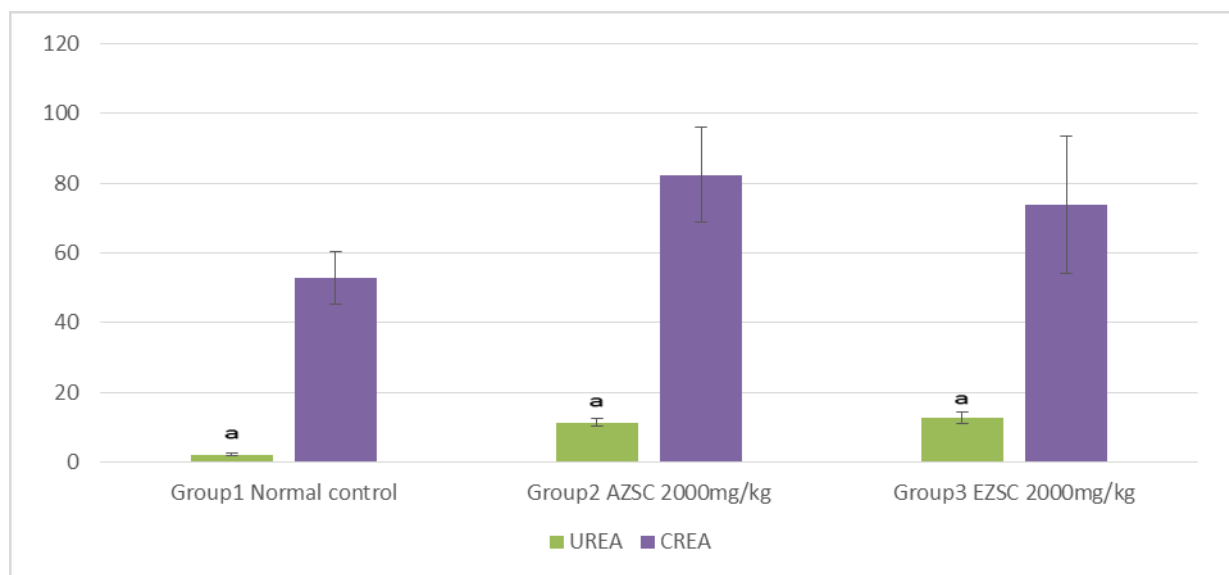
Values are expressed as the mean ± SEM of  $n=5$  in each group and were compared using one-way ANOVA. Differences with  $p < 0.05$  are considered statistically significant. AZSC: aqueous extract of *Z. spina-christi* fruit. EZSC: ethanol extract of *Z. spina-christi* fruit.

**Table 3. Effect of *Zizipus spina-christi* fruit aqueous and ethanol extracts on liver proteins in experimental rats**

GROUPS	Bilirubin	Conjugated bilirubin	Unconjugated bilirubin	Total protein	Albumin	Globulin
Normal control	5.33 ± 0.58*	2.95 ± 0.24	2.39 ± 0.58 <sup>a</sup>	6.99 ± 0.18	3.67 ± 0.07	3.32 ± 0.23
AZSC 2000 mg/kg	11.67 ± 0.33*	4.51 ± 0.16	7.16 ± 0.17 <sup>a</sup>	8.08 ± 0.18	4.03 ± 0.07	4.05 ± 0.21
EZSC 2000 mg/kg	10.33 ± 0.33*	3.93 ± 0.38	6.40 ± 0.08 <sup>a</sup>	9.70 ± 0.99	4.03 ± 0.07	5.67 ± 0.93

Values are expressed as the Mean ± SEM of n=5 in each group and were analyzed using one-way ANOVA. Differences with p<0.05 are considered statistically significant. Values with the same superscript (\* or <sup>a</sup>) are significantly different from the normal control group. AZSC: aqueous extract of *Z. spina-christi* fruit. EZSC: ethanol extract of *Z. spina-christi* fruit.

**Figure 2. Effect of *Zizipus spina-christi* fruit aqueous and ethanol extracts on urea and creatinine in experimental rats**



AZSC: aqueous extract of *Z. spina-christi* fruit. EZSC: ethanol extract of *Z. spina-christi* fruit.

single oral dose exposure of both the aqueous and ethanol extracts of *Z. spina-christi*. Animal treated with 2000 mg/kg of the two extracts showed no sign of toxicity within the 14 days of study. No animal died during the observation and no gross change in morphology was seen on all the major organs observed after the acute toxicity study. Figure 1 shows the weight of the animals treated with 2000 mg/kg of aqueous and ethanol extracts of *Z. spina-christi* for 14 days. The weight was recorded on days 0, 3, 7 and 14.

Table 2 shows effect of aqueous and ethanol extract of *Z. spina-christi* fruit on experimented rats on liver enzymes treated with 2000 mg/kg for 14 days. There is a significant difference between the normal control group and the treated group in alanine aminotransferase but no significant difference in aspartate aminotransferase. The AST/ALT ratio in the normal control group was 5:1 whereas in the treated group it was 2:1.

Concentration of total bilirubin, conjugated bilirubin, unconjugated bilirubin, total protein, albumin and globulin of experimental rats treated with 2000 mg/kg body weight of *Z. spina-christi* fruit aqueous and ethanol extracts are

presented in Table 3. In general, there is an increase in all the parameters tested in the two treated groups compared to the normal saline control group as shown in Table 4.

Urea and creatinine concentrations of experimental rats treated with 2000 mg/kg aqueous and ethanol extracts of *Z. spina-christi* fruit after 14 days of observation were determined. There is an increase in both the biomarkers, with a statistically significant difference to the normal control group. The details are shown in Figure 2.

## DISCUSSION

Whole plants and most of their parts have been in use for many years for their nutritional and medicinal values making them a part of alternative medicine, food pharmaceuticals, and natural therapies<sup>1,2</sup>. *Z. spina-christi* fruit is an example of such plant with high nutritional and medicinal values<sup>1,6-8</sup>. Presence of various secondary metabolites such as alkaloids, flavonoids, glycosides and tannins is believed to be reasons for the therapeutic properties of *Z. spina-christi* fruits<sup>13</sup>. Alkaloids, steroids, saponins, flavonoids, terpenoids, saponins glycoside, phytosteroids, cardiac

glycosides, tannins, volatile oil and carbohydrate in different concentration were the metabolites obtained from the phytochemical analysis of the aqueous and ethanol extracts of fruits of *Z. spina-christi*. The values of alkaloids, tannins, steroids, cardiac glycosides and volatile oil were shown to be higher in the ethanol extract than the aqueous extract. While saponins and terpenoids were more in aqueous than the ethanol extract. The concentration of carbohydrate and flavonoids were shown to be equal in the two extract solvents. This variation in the concentration of secondary metabolite in aqueous and ethanol extracts may be attributed to the polarity of the two solvents. This result is consistent with the finding of Trung et al.<sup>25</sup> on *Severinia buxifolia* that showed differences due to differences in the polarity of the extract solvents. Other studies<sup>1,6-9,14,26-28</sup> examined different parts of the plant including leaves, stem bark, root and seed oil and showed the presence of most of these compounds in different solvents. However, no volatile oil was seen in their extract, which may be attributed to the volatile nature of the compound.

An acute toxicity with a single oral dose of aqueous and ethanol extracts of *Z. spina-christi* fruit at 2000 mg/kg showed no sign of toxicity such as convulsion, vomiting, bleeding, breathing difficulties within the period of 14 days study. No animal died during the observation and no gross change in morphology was seen on all the major organs. This finding is in agreement with that of Abubakar et al.<sup>29</sup> who measured the LD<sub>50</sub> of the hydro-methanol extract of the fruit at a concentration of 5000 mg/kg<sup>29</sup>. They recorded zero toxicity, and no pathological changes on any major organ were seen with the naked eye.

The weight was recorded on days 0, 3, 7 and 14, and showed no significant difference. The rats continued to gain weight throughout the study period, the gain was more sustained in the control group than the two treatment groups. The food intake and water were also observed to be unaffected by the treatment. A weight reduction of 10% or more is usually considered very significant and usually depicts severe disease for which the toxicity of drug is one of them<sup>30</sup>.

Alanine aminotransferase and aspartate aminotransferase are important biomarkers of the liver. Elevated levels may indicate an abnormality such as hepatocellular injury due to either physical or chemical injuries<sup>31</sup>. The effect of aqueous and ethanol extracts of *Z. spina-christi* fruit on experimental rats after a single dose of 2000 mg/kg for 14 days, demonstrated significant differences between the normal control group and the treated group in alanine aminotransferase only, but not the aspartate aminotransferase. The AST/ALT ratio in the normal control group was 1:5 and in the treated groups was 1:2. The reverse of this enzyme ratio results from an increase in the level of ALT after the 2000 mg/kg dose of the extracts. ALT is an enzyme that is more specific to liver insult seen in drug toxicity, alcohol and many inflammatory conditions

of the liver. This result agrees with the finding of Marghoob et al.<sup>31</sup> who analyzed serum levels of alanine and aspartate aminotransferases, alkaline phosphatase and gamma glutamyl transferase, and concluded that comparative elevation indicates the degree of hepatic damage in viral hepatitis, alcoholic liver diseases, and cirrhosis. Sunmonu and Afolayan<sup>32</sup> similarly mentioned that elevation in ALT and AST suggested damage to the liver cells.

Concentration of total bilirubin, conjugated bilirubin, unconjugated bilirubin, total protein, albumin and globulin of experimental rats treated with 2000 mg/kg body weight of *Z. spina-christi* fruit aqueous and ethanol extracts shows an increase in all the parameters. Bilirubin is an important metabolic breakdown product of blood with biological and diagnostic values. It is removed from the body by the liver; hence, it is a good indicator of the health status of the liver<sup>32</sup>. Albumin and globulin are mixtures of protein molecules that are used to assess the health status of the liver. The two proteins are produced by the liver; albumin is a major carrier of drugs and many minerals that circulate in the bloodstream; globulins are larger proteins responsible for immunological responses<sup>32</sup>. The elevated serum level of bilirubin in experimental rats, as observed in the present study, may be a result of reduced uptake arising from liver disease.

Kidneys maintain chemical composition of body fluids by acidification of urine, and some excretal substances are released into the urine by active transport in the renal tubules. These substances include H<sup>+</sup> and K<sup>+</sup> ions, urea, and creatinine, as well as drugs such as penicillin. An elevated level of urea and creatinine are significant markers of kidney dysfunction indicating an inactivity in glomerular filtration rate<sup>33</sup>. The urea and creatinine concentrations of experimental rats treated with 2000 mg/kg aqueous and ethanol extracts of *Z. spina-christi* fruit after 14 days of observation show a significant elevation in both the biomarkers. These results suggest that a high dose of the *Z. spina-christi* fruit might be toxic to kidneys, even though the concentrations of urea and creatinine are within the normal range.

Liver histology was done using H&E stain to show distortion or otherwise of the liver architecture after 14 days study of the rats treated with both ethanol and aqueous extracts compared to normal control group (Supplementary file Figures 3–8). The liver architecture is well preserved in the normal control group. The central vein is clearly delineated surrounded by many sinusoids and few inflammatory cells. The nucleus was clearly seen and the nuclear cytoplasmic ratios are equal in most cell within the view. However, the liver architecture of the two treated groups was distorted. Tissue necrosis is seen as evidence by perinuclear vacuolation; also present are few inflammatory cells in the aqueous extracted treated group. The picture of ethanol treated rats is seen with some distortion as well, there are few inflammatory cells, the nuclei are moderately

pyknotic and the sinusoids are markedly reduced in space. This finding supports the liver enzyme and liver protein analyses of the study, both of which showed derangement after 14 days of study. The hepatocytes, portal triads and the sinusoids are usually the major parts of liver vulnerable to histological changes in liver toxicity<sup>33</sup>. Anisokaryosis, nuclear vesiculation, binucleation, cytoplasmic inclusions, cytoplasmic swelling, hydropic degeneration, necrosis and reduction in glycogen content were seen in lead toxicity of the liver<sup>34</sup>. Kupffer cells hyperplasia and occasional fatty changes of the portal triads together with hemosiderosis are also frequently seen.

Kidneys of the experimental rats from the control group show normal morphology as demonstrated by the presence of glomeruli surrounded by clear zones of capsular spaces and the glomerular capsules are intact. However, rats treated with a single dose of 2000 mg/kg aqueous extract of *Z. spina-christi* fruit showed glomerular atrophy and generalized tissue degeneration as seen by the dissolution of both nuclear and cytoplasmic components. Due to the degeneration, the nuclei are presented as naked nuclei. There is a lot of inflammation as demonstrated by the presence of several inflammatory cells within the tissue. Collagens deposition was seen in significant quantity around the glomerulus and the kidney tubules. Kidneys of experimental rats treated with 2000 mg/kg ethanol extracts also showed generalized tissue degeneration demonstrated by the presence of naked nuclei and the complete loss of nuclei in some cells. Increase in tubular spaces indicating tissue atrophy and mild collagenation shown by the presence of collagen fibers around the tubules are seen. The results of the two kidneys seen from histology, added weight to the increase in urea and creatinine obtained from blood analysis. Thus, both ethanol and aqueous extracts of this plant at the tested doses cause some liver and renal toxicity.

The same plant tested for toxicity in rats, at doses lower than ours given daily for 14 days, demonstrated a significant ( $p < 0.05$ ) reduction in the levels of white blood cells, neutrophils, serum aspartate amino transferase, Cl<sup>-</sup>, urea and creatinine. The lymphocytes, platelets, direct and total bilirubin, albumin, alanine amino transferase, alkaline phosphatase, aspartate aminotransferase, serum Ca<sup>2+</sup>, creatinine, and urea of rats were all elevated<sup>35</sup>. The liver and kidney architecture was not altered after the histological studies. This is likely due the use of doses lower than 2000 mg/kg used in this study.

### Limitations

The present study has several limitations that should be acknowledged. Firstly, the study used a qualitative phytochemical analysis approach, which did not provide quantitative data on the bioactive compounds present in the fruit extracts. Additionally, the study only evaluated the effects of the fruit extract on liver and kidney functions in Wistar rats, and did not investigate other potential toxic

effects on other organs or systems, or other animal models. Furthermore, the study had a limited sample size, which may impact the generalizability of the findings. Finally, the study used dried fruit purchased from local vendors, which may vary in quality, ripeness, and processing, potentially affecting the results.

### CONCLUSIONS

Our study provides valuable insights into the phytochemical composition and toxicological effects of *Z. spina-christi* fruit extracts. The findings indicated that it can be toxic at higher doses. Specifically, our results demonstrated that high doses of the fruit extract can cause significant alterations in liver enzymes, urea, creatinine, and liver proteins, as well as histological changes in the liver and kidneys. The study contributed to the growing body of knowledge on the potential uses and limitations of *Z. spina-christi* fruit extracts. Our findings highlight the importance of thorough toxicological evaluation of traditional remedies and provide a foundation for future studies to build upon. The study's use of dried fruit from local vendors also reflects the typical consumption habits of the local community, making the findings more relevant and applicable to real-world scenarios. Overall, our research emphasizes the need for a balanced approach to traditional medicine, combining the benefits of natural remedies with rigorous scientific evaluation to ensure safe and effective use.

### REFERENCES

1. Bukar AM, Kyari MZ, Gwaski PA, Gudusu M, Kuburi FS, Abadam YI. Evaluation of phytochemical and potential antibacterial activity of *Ziziphus spina-christi* L. against some medically important pathogenic bacteria obtained from University of Maiduguri Teaching Hospital, Maiduguri, Borno State – Nigeria. *Journal of Pharmacognosy and Phytochemistry*. 2015;3(5):98-101.
2. Mohammed, GT, Abdulrahman FI, Khan IZ, Hussaini MI, Muazu J, Yakubu S. Antimicrobial efficacies of ethanolic extract and active column fractions of the stem-bark of *Zizyphus Spina-Christi* L. (Desf). *International Journal of Pharmacy and Pharmaceutical Sciences*; 201;5(1):455-459.
3. Sofowora A. *Medicinal plants and traditional medicine in Africa*. John Wiley, New York; 1984:256-257.
4. Katzung, BG. *Basic and Clinical Pharmacology*. 9th ed. London: Prentice Hall International (UK) Limited; 2005. Accessed February 20, 2024. [https://pharmacomedicale.org/images/cnpm/CNPM\\_2016/katzung-pharmacology.pdf](https://pharmacomedicale.org/images/cnpm/CNPM_2016/katzung-pharmacology.pdf)
5. Meresa A, Worku G, Hirut B, et al. Herbal medicines for the management of diabetic mellitus in Ethiopia and Eritria including their phytochemical constituents. *American Journal of Advanced Drug Delivery*. 2017;05(01). doi:10.21767/2321-547X.1000011
6. Abalaka, ME, Daniyan SY, Mann A. Evaluation of the antimicrobial activities of two *Ziziphus* species (*Ziziphus mauritiana* L. and *Ziziphus spina-christi* L.) on some microbial

- pathogens. *Afr. J. Pharm. Pharmacol.* 2010;4(4):135-139.
7. Yossef HE, Khedr AA, Mahran MZ. Hepatoprotective activity and antioxidant effects of El Nabka (*Zizyphus spina-christi*) fruits on rats hepatotoxicity induced by carbon tetrachloride. *Nat. Sci.* 2011;9(2):1-7.
  8. Asgarpanah J, Haghghat E. Phytochemistry and pharmacologic properties of *Zizyphus spina christi* (L.) Willd. *African Journal of Pharmacy and Pharmacology.* 2012;6(31). doi:[10.5897/AJPP12.509](https://doi.org/10.5897/AJPP12.509)
  9. Glombitza KW, Mahran GH, Mirhom YW, Michel KG, Motawi TK. Hypoglycemic and antihyperglycemic effects of *Zizyphus spina-christi* in rats. *Planta Med.* 1994;60(3):244-247. doi:[10.1055/s-2006-959468](https://doi.org/10.1055/s-2006-959468)
  10. Mostafa M, Takano F, Ohta T. Unique phenyl ether type Biflavonoids, *Zizyflavosides A and B* with biomimetic synthesis for *Zizyflavoside A*, Heterocycles. 2010;81(11):2497–2509. doi:[10.3987/com-10-12002](https://doi.org/10.3987/com-10-12002).
  11. Mostafa M, Takano F, Ohta T. P-54 New biflavonoyl ether glycosides from *Zizyphus spina-christi*: symmetrical ether derived from two different flavonoids. In *Symposium on the Chemistry of Natural Products.* 2010;52(52):631-635. doi:[10.24496/tennenyuki.52.0\\_631](https://doi.org/10.24496/tennenyuki.52.0_631)
  12. Mostafa MAH, Khojah HMJ, Ohta T. Isolation and identification of novel selective antitumor constituents, sidrin and sidroside, from *Zizyphus spina-christi*. *Saudi Pharm J.* 2023;31(6):1019-1028. doi:[10.1016/j.jsps.2023.04.029](https://doi.org/10.1016/j.jsps.2023.04.029)
  13. Nuru KA, Garkuwa UA, Yusuf H, Tijjani H, Kura AU. Hypoglycaemic potential of *Zizyphus Spina-Christi* Fruit on Alloxan Induced Hyperglycaemic Rats. *Journal of Bioequivalence Studies.* 2022;8(1):102.
  14. Adzu B, Haruna AK. Studied on the use of *Zizyphus spina-christi* against pain in rats and mice. *Afr. J. Biotechnol.* 2007;6(11):1317-1324.
  15. Khojah HMJ, Abdelhalim OB, Mostafa MAH, Habib EE. Antimicrobial efficacy of extracts of Saudi Arabian desert *Terfezia claveryi* truffles. *Saudi J Biol Sci.* 2022;29(11):103462. doi:[10.1016/j.sjbs.2022.103462](https://doi.org/10.1016/j.sjbs.2022.103462)
  16. Shen X, Tang Y, Yang R, Yu L, Fang T, Duan JA. The protective effect of *Zizyphus jujube* fruit on carbon tetrachloride-induced hepatic injury in mice by anti-oxidative activities. *J Ethnopharmacol.* 2009;122(3):555-560. doi:[10.1016/j.jep.2009.01.027](https://doi.org/10.1016/j.jep.2009.01.027)
  17. Association of Official Analytical Chemists. *Official Method of Analysis.* 13th ed. AOAC; 1984:16-32.
  18. Trease GE, Evans WC. *Pharmacognosy.* 11th ed., BailliereTindall; 1989:45-50.
  19. OECD. Test No. 420: Acute Oral Toxicity - Fixed Dose Procedure. OECD Publishing; 2002. doi:[10.1787/9789264070943-en](https://doi.org/10.1787/9789264070943-en)
  20. Reitman S, Frankel S. A colorimetric method for the determination of serum glutamic oxalacetic and glutamic pyruvic transaminases. *Am J Clin Pathol.* 1957;28(1):56-63. doi:[10.1093/ajcp/28.1.56](https://doi.org/10.1093/ajcp/28.1.56)
  21. Chaney AA, Marbach PP. Modified reagents for determination of urea and ammonia. *Clinical Chemistry.* 1962;8:130–132. doi:[10.1093/clinchem/8.2.130](https://doi.org/10.1093/clinchem/8.2.130)
  22. Taussky HH. Creatinine and creatinine in urine and serum, in: *standard methods of clinical chemistry,* Seligson D, ed, 3rd ed, New York Academic Press. 1961:99–113. doi:[10.1016/B978-1-4831-9684-8.50015-6](https://doi.org/10.1016/B978-1-4831-9684-8.50015-6)
  23. Coles EH. *Veterinary Clinical Pathology.* 3rd edition. Philadelphia: W.B Saunders& Co; 1:192–222.
  24. Carleton H. *Histological techniques.* 4th edition. London: Oxford University Press; 1980.
  25. Trung D, DinhHieu N, NhatThuy AT, AnhVo B, Tuong HD, Hoang CN. Evaluation of the use of different solvents for phytochemical constituents, antioxidants, and in vitro anti-inflammatory activities of *Severinia buxifolia*. *Journal of Food Quality.* 2019;2019:1-9. doi:[10.1155/2019/8178294](https://doi.org/10.1155/2019/8178294)
  26. Ibrahim JA, Egharevba HO, Nnamdi RA, Kunle OF. Comparative pharmacognostic and phytochemical analysis of *Zizyphus spina-christi* (L.) Desf. and *Zizyphus abyssinica* Hochst. Ex A. Rich. *International Journal of Pharmacognosy and Phytochemical Research.* 2015;7(6):1160-1166.
  27. Kamalu, AA, Aisha SI, Manjur MS. Phytochemical analysis, proximate composition and antibacterial activities of *Zizyphus* species (*Z. jujube* and *Z. spina-christi*). *Journal of Applied and Advanced Research.* 2019;4(1)42-46. doi:[10.21839/jaar.2019.v4i1.262](https://doi.org/10.21839/jaar.2019.v4i1.262)
  28. Alhakmani F, Khan SA, Ahmad A. Determination of total phenol, in-vitro antioxidant and anti-inflammatory activity of seeds and fruits of *Zizyphus spina-christi* grown in Oman. *Asian Pac J Trop Biomed.* 2014;4:S656–S660. doi:[10.12980/APJTB.4.2014APJTB-2014-0273](https://doi.org/10.12980/APJTB.4.2014APJTB-2014-0273)
  29. Abubakar SM, Sufyan AU, Idoko A, Nura A, Mansurah AA, Muhammad SS. Evaluation of hypoglycaemic, hypolipidaemic and non toxic effect of hydro-methanolic extracts of *Zizyphus Mauritiana*, *Zizyphus Spina Christi* fruit and glibenclamide on alloxan induced diabetic rats. *Journal of Drug Delivery and Therapeutics.* 2018;8(3). doi:[10.22270/jddt.v8i3.1711](https://doi.org/10.22270/jddt.v8i3.1711)
  30. Chapman K, Sewell F, Allais L, et al. A global pharmaceutical company initiative: an evidence-based approach to define the upper limit of body weight loss in short term toxicity studies. *Regul Toxicol Pharmacol.* 2013;67(1):27-38. doi:[10.1016/j.yrtph.2013.04.003](https://doi.org/10.1016/j.yrtph.2013.04.003)
  31. Marghoob H, Mohd AH, Abdelmarouf HM. Comparative levels of ALT, AST, ALP and GGT in liver associated diseases. *Pelagia Research Library European Journal of Experimental Biology.* 2013;3(2):280-284.
  32. Sunmonu TO, Afolayan AJ. Evaluation of antidiabetic activity and associated toxicity of *Artemisia afra* Aqueous extract in wistar rats. *Evid Based Complement Alternat Med.* 2013;2013:929074. doi:[10.1155/2013/929074](https://doi.org/10.1155/2013/929074)
  33. Berrredjem H, Reggami Y, Benlaifa M, Berrredjem M, Bouzerna N. Antidiabetic and hypolipidemic potential of 3,-dihydro isoquinolin-2 (1H)-sulfanamide in Alloxan induced diabetic rats. *International Journal of Pharmacology.* 2015;11(3):226-235. doi:[10.3923/ijp.2015.226.235](https://doi.org/10.3923/ijp.2015.226.235)
  34. Bashir MJ, Noory TT. Histological and histochemical alterations in the liver induced by lead chronic toxicity. *Saudi Journal of Biological Sciences.* 2012;19:203-210. doi:[10.1016/j.j](https://doi.org/10.1016/j.j)



[sjbs.2011.12.005](#)

35. Owolarafe TA, Salau AK, Salawu K. Phytochemical screening and toxicity study of aqueous-methanol extract of Ziziphus spina-christi seeds in Wistar albino rats. Comparative Clinical Pathology. 2020;29:267–274. doi:[10.1007/s00580-019-03043-5](#)

#### ACKNOWLEDGEMENTS

We would like to thank Departments of Biochemistry and Pharmacology of Bauchi State University Gadau for the space and equipment provided in carrying out this study. We also thank the taxonomist Umar Aminu Muhammad for his help.

#### CONFLICTS OF INTEREST

The authors have completed and submitted the ICMJE Form for Disclosure of Potential Conflicts of Interest and none was reported.

#### FUNDING

There was no source of funding for this research.

#### ETHICAL APPROVAL AND INFORMED CONSENT

Ethical approval was obtained from the Faculty of Basic Medical Science Research and Ethics Committee (FBMSREC) Bauchi State University Gadau (Approval number: BASUG/FBMSREC/VOL. 2/002).

#### DATA AVAILABILITY

The data supporting this research are available from the authors on reasonable request.

#### AUTHORS' CONTRIBUTIONS

KAN performed the experiment, analysis and the initial writing of the manuscript. HY, HT, UAG and AUK were involved with the conceptual design of the experiment, drafting of the manuscript, and intellectual revision. All authors read and approved the final version of the manuscript.

#### PROVENANCE AND PEER REVIEW

Not commissioned; externally peer reviewed.